

After the History, After the Physical, It's CYTOLOGY to the Rescue


Karen A. Moriello DVM DACVD
Clinical Professor of Dermatology
University of Wisconsin-Madison

Leon Congress 2019

Do we have a *plan* or do we need **MORE TESTS?**

Leon Congress 2019

Major Take Home Pearl



Leon Congress 2019

Sample Acquisition Tools




Leon Congress 2019

What we do, all the time, every time

- Dermatology "TPR" (included in exam fee)
 - Hair combing
 - Hair trichogram
 - Ear swab cytology
 - Routine for staining
 - Mineral oil-even in adult animals
- Skin cytology


Leon Congress 2019

Things that PLUG-IN



345 nm with magnification
Well maintained microscope for cytology


Leon Congress 2019




A few words from the microscope repair person

- Having objectives you don't use....
- Using TOO much immersion oil
- Not cleaning microscope lens with LENS paper
- Not using OFFICIAL lens cleaner
- Not moving the objective before removing the slide
- **NOT COVERING THE SCOPE WHEN NOT IN USE**
- Of course, not having them routinely serviced


Leon Congress 2019





Scrape area and pluck hairs for best sampling in suspected dermatophyte cases


Leon Congress 2019




More Useful Direct Examinations

(hair plucks and skin scrapings and anything else in mineral oil)

Leon Congress 2019






Leon Congress 2019

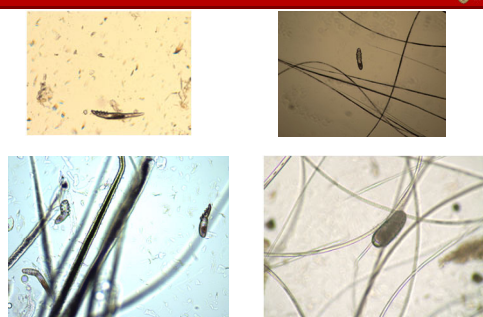


Take Home Pearls

- Use heavy mineral oil for all sampling
- DO NOT USE 'clearing agents'
 - Not beneficial
 - Caustic agents and pose risk to equipment and people/animals
 - Introduce artifacts
- Mix mineral oil and 'blue stain'.....
- Coverslip samples, practice hurry up and wait.....

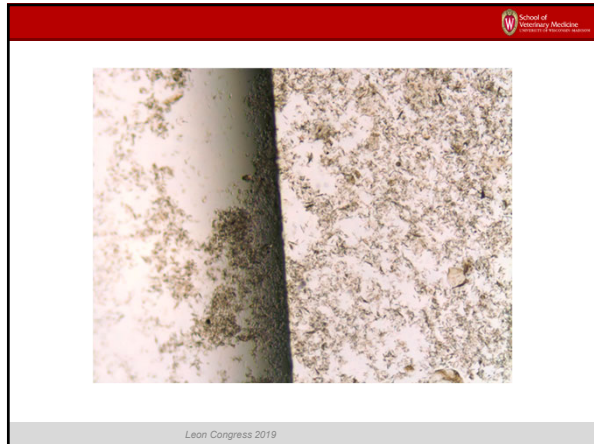
Leon Congress 2019





Cheyletiella egg

Leon Congress 2019



School of Veterinary Medicine
University of Pennsylvania

ICU Kitten, total WBC <1000, URI, Diarrhea, can you do a derm consult?

Leon Congress 2019

School of Veterinary Medicine
University of Pennsylvania

Practice Tip: Coverslip and examine edges for parasites

Leon Congress 2019

School of Veterinary Medicine
University of Pennsylvania

Direct examinations can be done from hairs trapped in toothbrush samples

Leon Congress 2019

School of Veterinary Medicine
University of Pennsylvania

Dermatophytes- abnormal hairs are easily seen at low power

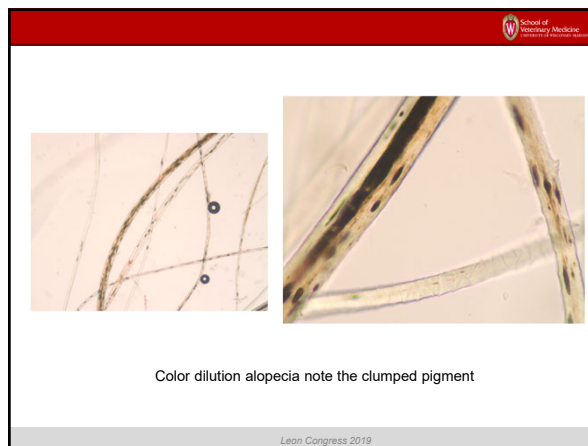
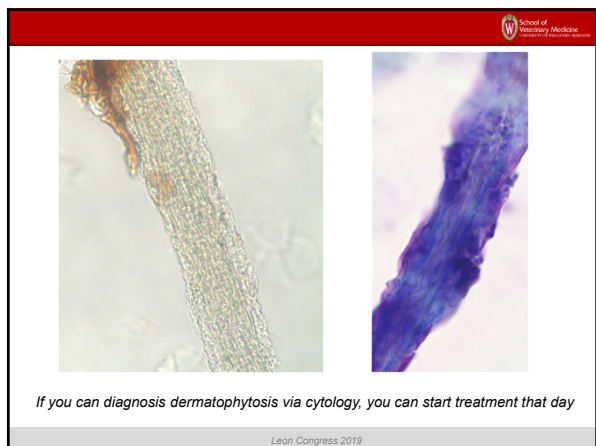
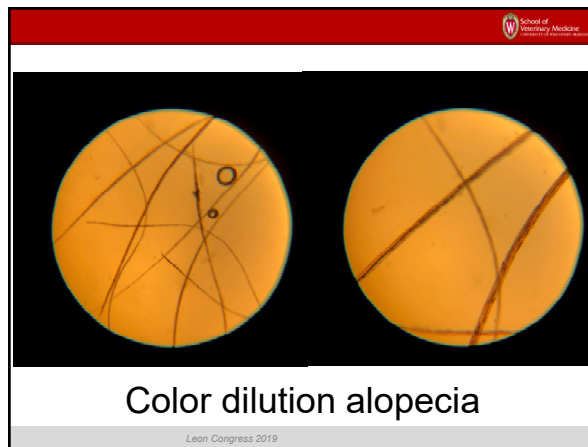
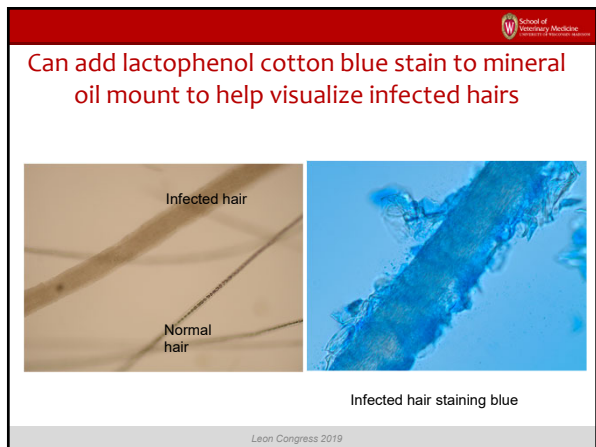
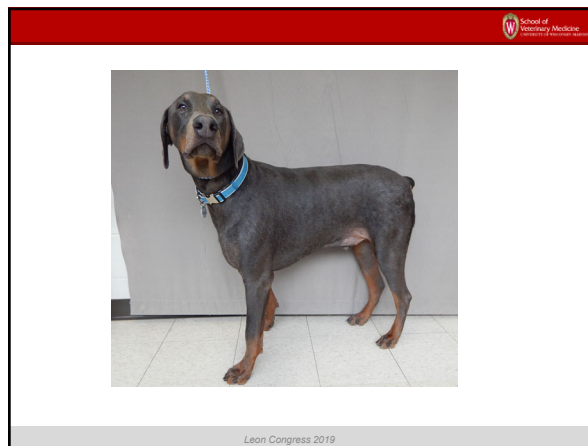
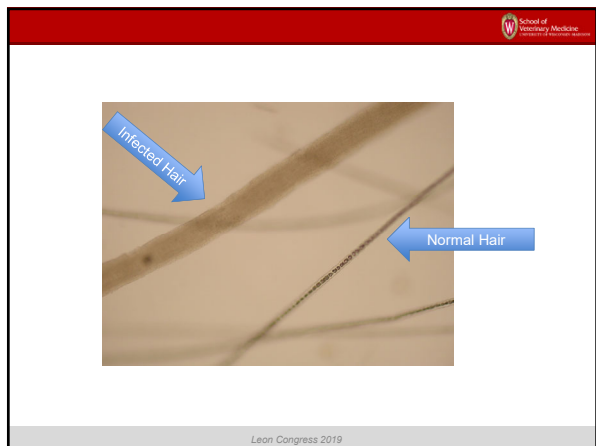
Leon Congress 2019


School of Veterinary Medicine
University of Pennsylvania

Infected hairs pale, wide

Normal hairs, thin, threadlike

Leon Congress 2019





More Useful Cytological Examinations (anything with stain)

Leon Congress 2019



Avoiding Artifacts and Staining Problems



Cover Stains Bottles






Remove organic debris

Change stains often (at least 1x/week)
Use clean new containers


Leon Congress 2019




Getting Better Stained Samples


- Allow wet mounts to dry before fixative step
- DO NOT HEAT FIX ANY SAMPLES-not needed
- Ear-roll samples to prevent cell damage
- Good stain hygiene
- Blot off excess stain before moving to next stain bottle
- Rinse with distilled water-less streaking
- Do not examine wet mounts
- 4x, 10x and oil immersion (100x)

Leon Congress 2019








Leon Congress 2019



Rapid In House Stains







Leon Congress 2019





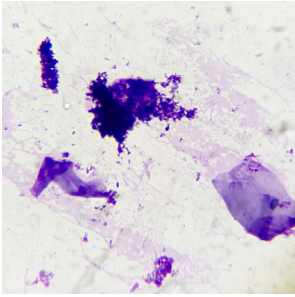




Leon Congress 2019

School of Veterinary Medicine
University of Wisconsin-Madison


Stain precipitate



Leon Congress 2019

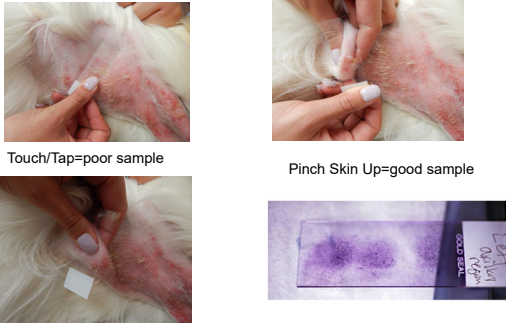
School of Veterinary Medicine
University of Wisconsin-Madison

Clear Tape For Hard To Sample Sites



Leon Congress 2019

School of Veterinary Medicine
University of Wisconsin-Madison



Touch/Tap=poor sample

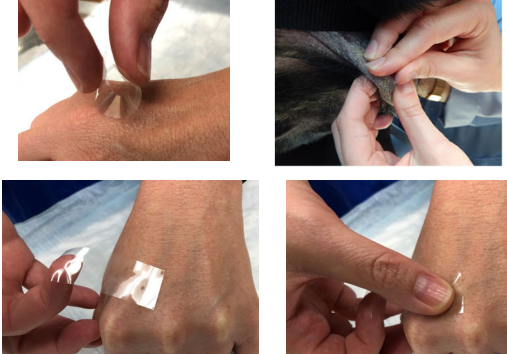
Pinch Skin Up=good sample

Sandwiching Technique=good sample

Use one site per press or

Leon Congress 2019

School of Veterinary Medicine
University of Wisconsin-Madison



Leon Congress 2019

School of Veterinary Medicine
University of Wisconsin-Madison

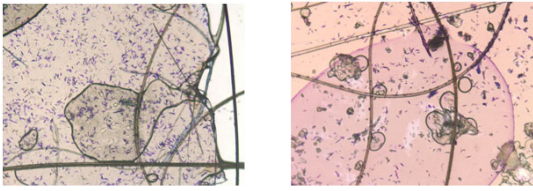
Get Samples From Beneath a Crust (For Cytology and Culture)



Leon Congress 2019

School of Veterinary Medicine
University of Wisconsin-Madison

HATE Tape Cytology?



Leon Congress 2019

School of Veterinary Medicine
University of Wisconsin - Madison

Don't Like Tape Preps? Maybe You Can

Poor techniques

Stain tape alone, let dry, mount over immersion oil, then examine

Leon Congress 2019

School of Veterinary Medicine
University of Wisconsin - Madison

Nail Bed Cytology

Leon Congress 2019

School of Veterinary Medicine
University of Wisconsin - Madison

Common Artifacts

Keratohyalin granules

Melanin granules

Lipids

Epidermal Lipids

Leon Congress 2019

School of Veterinary Medicine
University of Wisconsin - Madison

Sample With Spatula

Leon Congress 2019

School of Veterinary Medicine
University of Wisconsin - Madison

Pollens

Macroconidia are NEVER seen on direct examinations

Leon Congress 2019

School of Veterinary Medicine
University of Wisconsin - Madison

Yes, there is paw licking even if you don't see it...

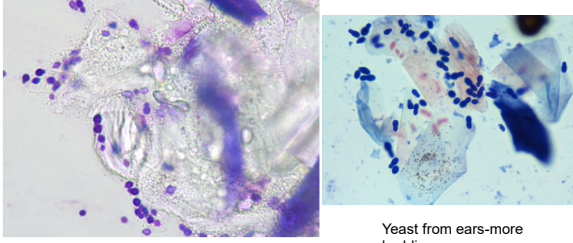
cocci

Simonsiella oral flora

Leon Congress 2019

School of Veterinary Medicine
University of Wisconsin-Madison

Yeast Overgrowth




Yeast on skin often show less budding and are 'rounder'

Yeast from ears-more budding

Leon Congress 2019

School of Veterinary Medicine
University of Wisconsin-Madison

Beware of Cats



Leon Congress 2019

School of Veterinary Medicine
University of Wisconsin-Madison

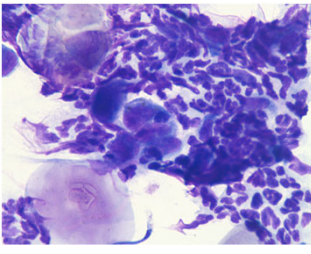
Canine-Nail Bed Bacteria



Leon Congress 2019

School of Veterinary Medicine
University of Wisconsin-Madison

Cats with Paronychia

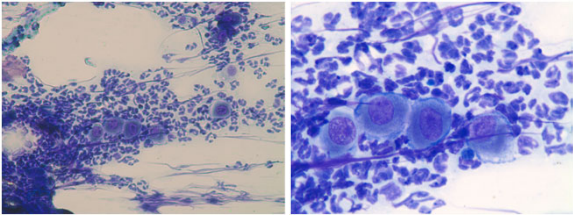


Consider Pemphigus or but look close for dermatophytosis

Leon Congress 2019

School of Veterinary Medicine
University of Wisconsin-Madison

Dog or Cat with Exudative Paronychia

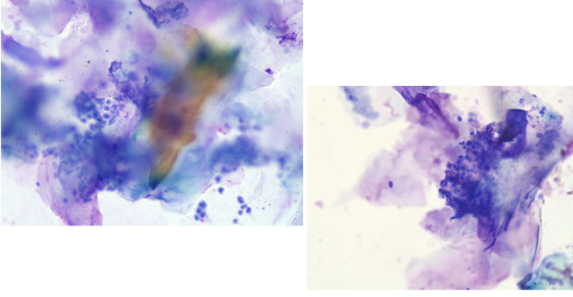


Pemphigus

Leon Congress 2019

School of Veterinary Medicine
University of Wisconsin-Madison

Dermatophytosis



Leon Congress 2019

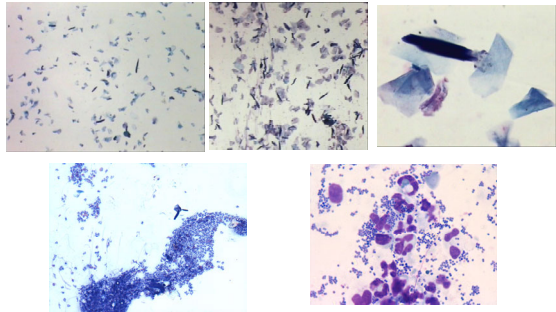
School of Veterinary Medicine
University of Pennsylvania

Excessive Scaling (everywhere) (may or may not be ill)

Leon Congress 2019


School of Veterinary Medicine
University of Pennsylvania

Scan: Inflammatory or Not?



Leon Congress 2019

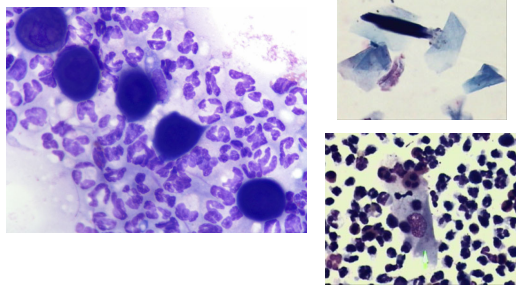
School of Veterinary Medicine
University of Pennsylvania



Leon Congress 2019

School of Veterinary Medicine
University of Pennsylvania

Keratinocytes: Round or Angular?



Leon Congress 2019

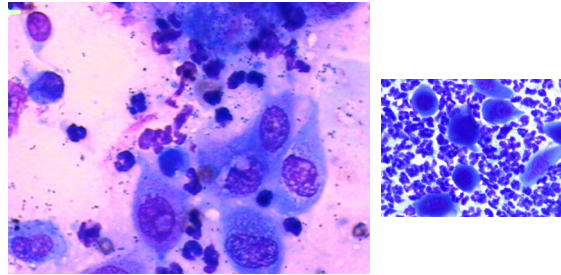
School of Veterinary Medicine
University of Pennsylvania

Lesions on Concave Pinnae Could Be Anything But Not Normal



Leon Congress 2019

School of Veterinary Medicine
University of Pennsylvania

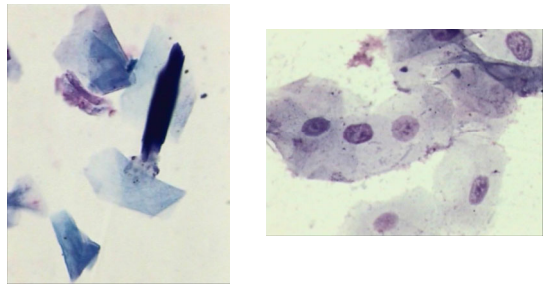


Rounded, nucleated keratinocytes may be from denuded ulcer or deep pyoderma or may be suggestive of pemphigus... look for bacteria and lesion distribution

Leon Congress 2019

School of Veterinary Medicine
University of Wisconsin-Madison

Angular Keratinocytes: Nucleated or Not



Leon Congress 2019

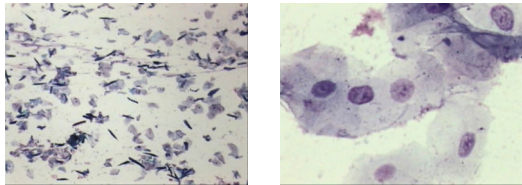
School of Veterinary Medicine
University of Wisconsin-Madison

“It looks like pyoderma and otherwise healthy” (most common, can be very frustrating)

Leon Congress 2019

School of Veterinary Medicine
University of Wisconsin-Madison


Non-Inflammatory Angular Nucleated Keratinocytes



Parakeratosis-Consider disorder of keratinization or zinc responsive skin disease

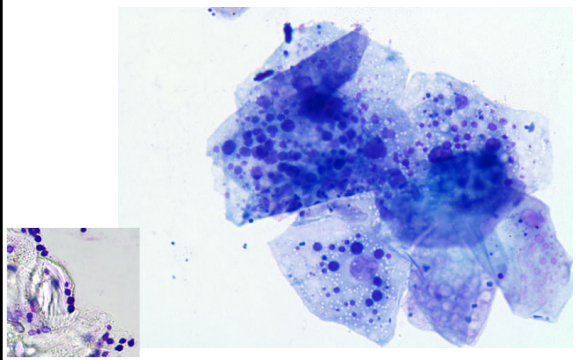
Leon Congress 2019

School of Veterinary Medicine
University of Wisconsin-Madison



Leon Congress 2019

School of Veterinary Medicine
University of Wisconsin-Madison



Leon Congress 2019

School of Veterinary Medicine
University of Wisconsin-Madison

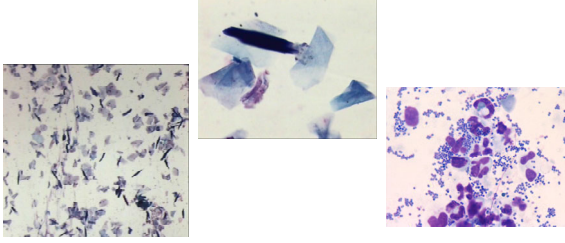
Pustules in Otherwise Healthy Pets Not a Problem



Leon Congress 2019

School of Veterinary Medicine
Leon College of Veterinary Medicine

Scan: May or May Not Be Inflammatory
Keratinocytes are Non-Nucleated and Angular in Pyoderma



Leon Congress 2019

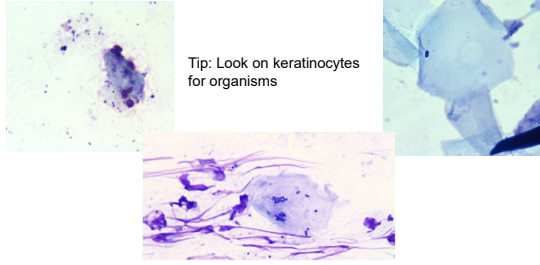
School of Veterinary Medicine
Leon College of Veterinary Medicine

Things Cats Do

Leon Congress 2019

School of Veterinary Medicine
Leon College of Veterinary Medicine

Pyoderma-Clinical Diagnosis
Hope to Find Cocci But Look For Yeast

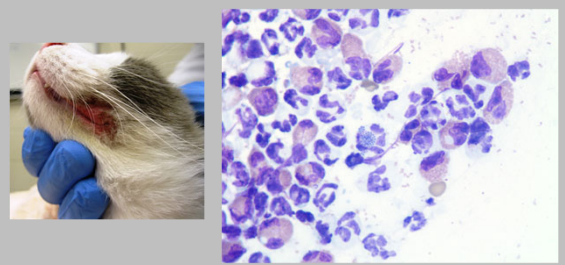


Tip: Look on keratinocytes for organisms

Leon Congress 2019

School of Veterinary Medicine
Leon College of Veterinary Medicine

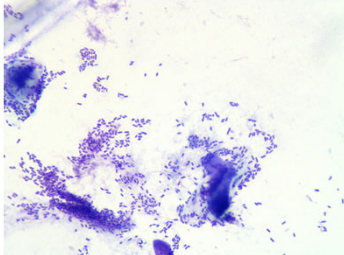
Cat Pyoderma-Eosinophils Are Common Inflammatory Cell



Leon Congress 2019

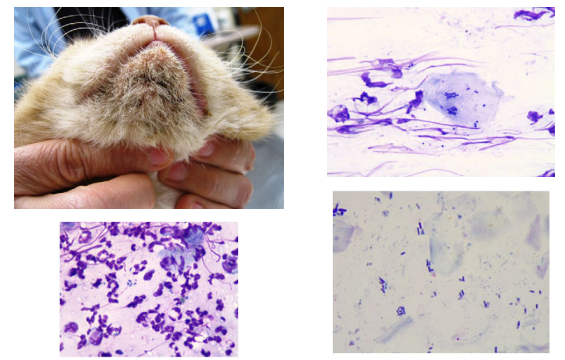
School of Veterinary Medicine
Leon College of Veterinary Medicine

Dog, Bacterial Pyoderma, Rods..
Could be *Pseudomonas* Pyoderma




Leon Congress 2019

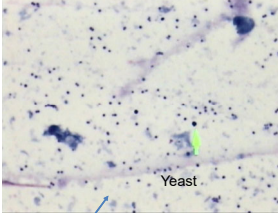

School of Veterinary Medicine
Leon College of Veterinary Medicine



Leon Congress 2019




Cats: Cocci and Yeast



Cocci

Yeast


Leon Congress 2019



Quick Guide

- (1) Inflammatory
 - Infection only clues?
 - Could this be an immune mediated/autoimmune disease?
- (2) Keratinocytes (round or angular)
 - Round, deeply basophilic-pemphigus or deep infection
 - Angular-likely pyoderma
- (3) Keratinocytes (nucleated or not)
 - Nucleated and round-pemphigus or deep infection
 - Nucleated and angular-disorders of keratinization
 - Non-nucleated and angular-likely pyoderma
- (4) Microbe hunt

Leon Congress 2019



Thank you for your attention!

Leon Congress 2019