

POINT OF CARE DIAGNOSTICS Practice Tips

Karen A. Moriello DVM DACVD
Clinical Professor of Dermatology
University of Wisconsin-Madison

Leon Congress 2019

Awkward Comments

- Student or Technician to Doctor.....
 - *I didn't see anything on the slide*
 - *There wasn't anything there*
 - *There was nothing on the slide*
 - *It didn't tell me anything.....*
- There were no X (mites, micro-organisms, etc..) observed
- The test results are available and to remind you this was the our question....
- These normal findings are reassuring because...

Leon Congress 2019

More is missed for not
looking than not knowing

AND

Without diagnostics you are just
guessing

Leon Congress 2019

#1
Schedule MORE
time and charge
appropriately

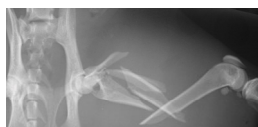Leon Congress 2019

**No one happily pays
for "nothing"**

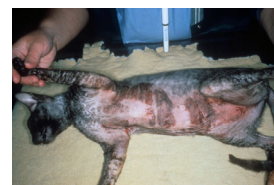Leon Congress 2019

FRONT END WORK

"Back end" time load-doctor/case
dependent



"Front end" time load-client
dependent



Leon Congress 2019

School of Veterinary Medicine
University of Liverpool

#2

Include the cost of core diagnostics in the examination fee

Leon Congress 2019

School of Veterinary Medicine
University of Liverpool

Dermatology “Go Kit”



Leon Congress 2019

School of Veterinary Medicine
University of Liverpool

Dermatology TPR

- Skin cytology
- Ear swab cytology
- Trichogram
- Skin scraping
- Wood's lamp examination

Leon Congress 2019

School of Veterinary Medicine
University of Liverpool

#4

Don't waste money on low yield diagnostic tests

Leon Congress 2019

School of Veterinary Medicine
University of Liverpool

#3

Have “Derm Diagnostics” kit ready to GO

Leon Congress 2019

School of Veterinary Medicine
University of Liverpool

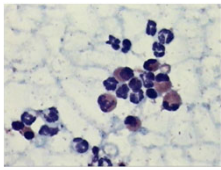
Otherwise Healthy Pet

- Serum chemistry panel
- Urinalysis
- FeLV/FIV
- Tick Titers
- Isolated T4
- Isolated cortisol
- Complete blood count?

1.4 Aspects of Feline Symmetric Alopecia

K.L. Thoday


Senior Lecturer in Veterinary Medicine, Department of Veterinary Clinical Studies
Royal (Dick) School of Veterinary Studies, University of Edinburgh, Edinburgh, Scotland




Leon Congress 2019

#5
Do hair trichograms

Leon Congress 2019

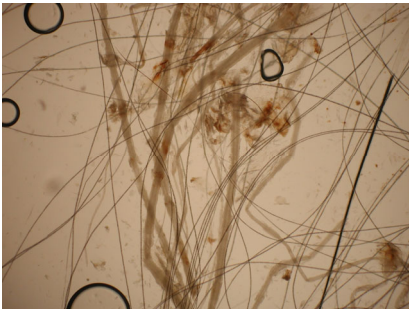


Leon Congress 2019




Safer, allows for easier sampling of patients,
allows for sampling of sensitive body site areas

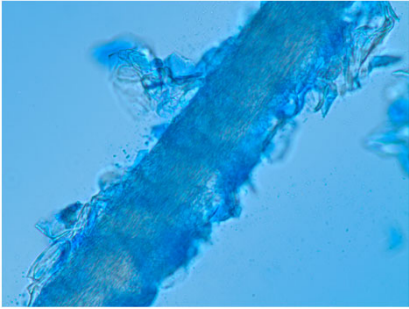
Leon Congress 2019



Leon Congress 2019



Leon Congress 2019



Use Lactophenol
cotton blue


Use new
methylene blue

#2 from DiffQuik

Leon Congress 2019

#6 Get one GOOD Wood's Lamp

Leon Congress 2019



Leon Congress 2019

Wood's Lamp Practice Tips

Use medical grade lamp, do not use battery operated lights

Use Wood's lamp with magnification

Hold lamp CLOSE to skin (2-4 cm)

Start on head and move slowly

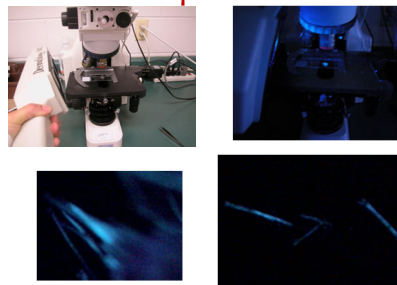
LIFT crusts, only **hair shafts glow**

Newly infected hairs are very short

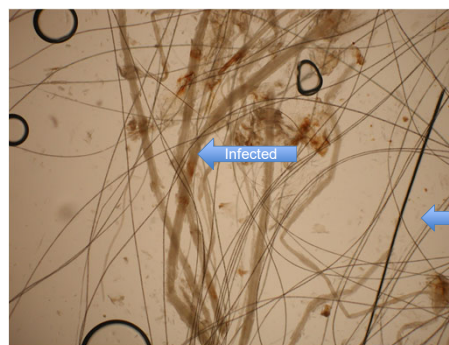Worried about false fluorescence? Look at hair root



Wood's Lamp Use In Laboratory



Leon Congress 2019



Leon Congress 2019

#7

Use a skin scraping spatula instead of a scalpel blade

Leon Congress 2019

#8

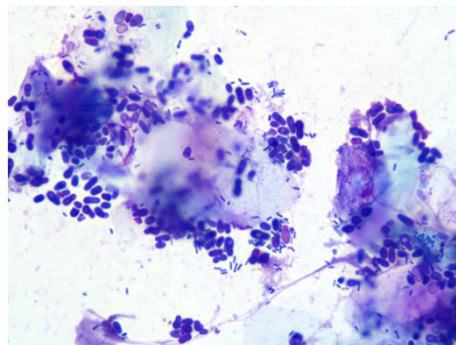
Getting better cytology samples

Leon Congress 2019

Skin Scraping Spatula



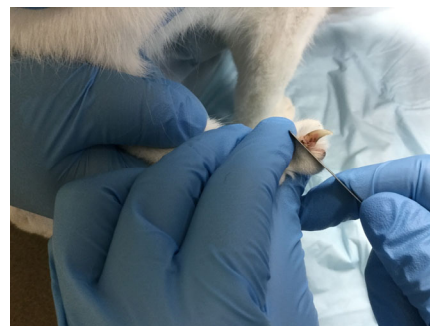
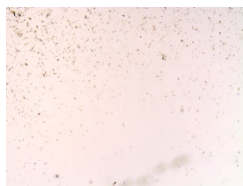
Blood borne diseases: pets and people



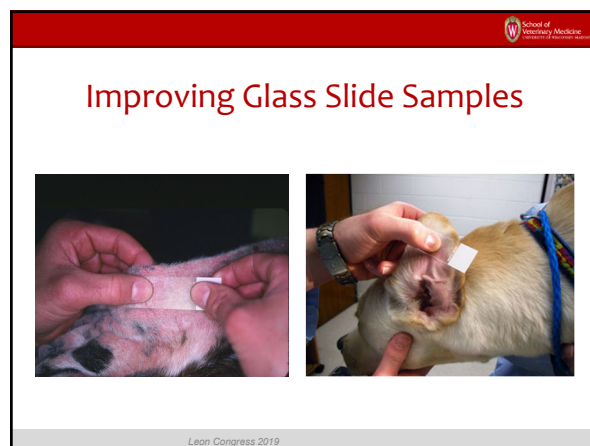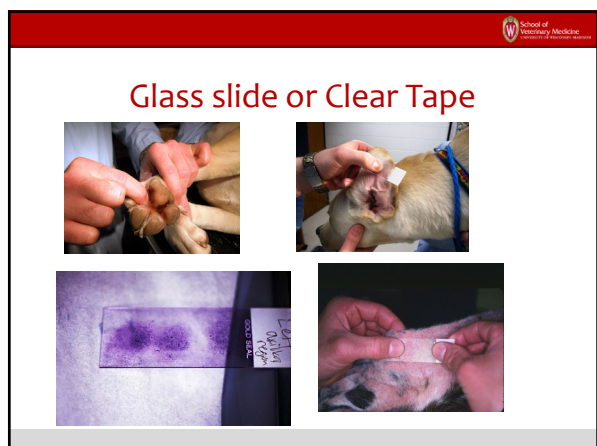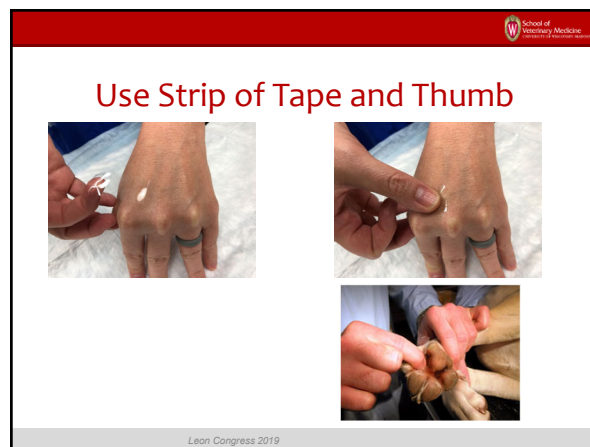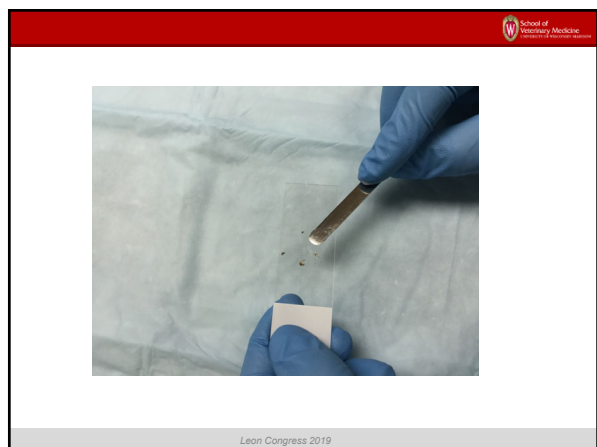
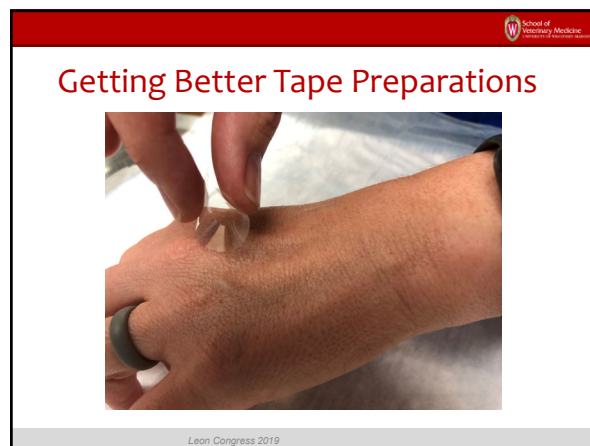
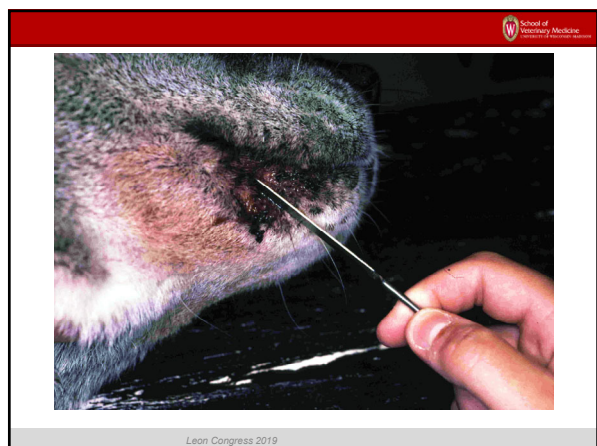
Leon Congress 2019

Practice Hurry up and Wait

- Always use a coverslip
- Puts mites into one plane for visualization
- WAIT to examine until the weight of the coverslip "pushes" debris to the edges



Leon Congress 2019




Good glass slide you see imprint



Leon Congress 2019

Keep Covered, Change Often



Leon Congress 2019

DO NOT HEAT FIX SLIDES




Leon Congress 2019

Skip Fixative, Stain Tape, Blot Stain Between Stains



Leon Congress 2019

USE DISTILLED WATER RINSE



Less Streaking


Leon Congress 2019

Do NOT Mount Tape on Slide For Staining

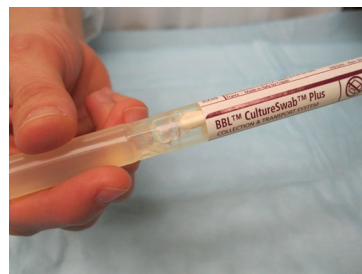


Leon Congress 2019

Mount Tape Cytology Over Drop of Immersion Oil



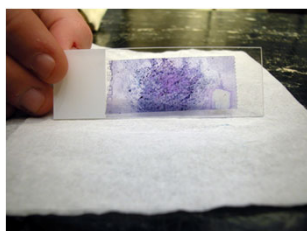
Leon Congress 2019



Use LARGE surface area swab, pre-moisten with transport medium

Leon Congress 2019

Final Product.....

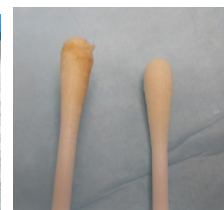
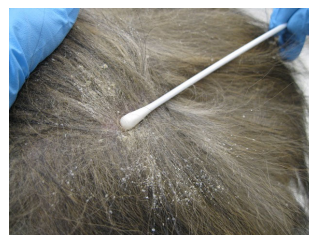
4X

10 X

Oil
Immersion

Leon Congress 2019

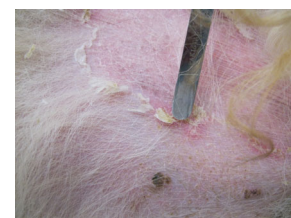
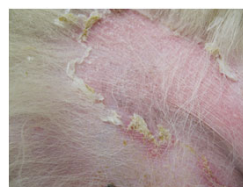
Aggressively rub swab, rotate 360°, until entire surface is soiled

Leon Congress 2019

#9 Minimizing “No growth” Bacterial Cultures

Leon Congress 2019



Use skin scraping spatula to 'lift' lesion edges for sampling

Leon Congress 2019

School of Veterinary Medicine
University of Pennsylvania

#10


In House Fungal Cultures

To do or not to do?

Leon Congress 2019

School of Veterinary Medicine
University of Pennsylvania

Toothbrush Fungal Culture



Leon Congress 2019

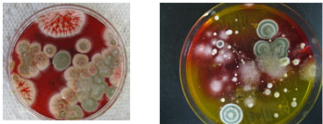
School of Veterinary Medicine
University of Pennsylvania

Veterinary Dermatology

Ver Dermatol 2016; 27: 284-e08 DOI: 10.1111/vid.12322

Comparison between point-of-care dermatophyte test medium and mycology laboratory culture for diagnosis of dermatophytosis in dogs and cats

Ronnie Kaufmann*, Shlomo E. Blum†, Daniel Elad† and Gila Zur*



Follow Instructions: 3% chance of error
Don't follow instructions: > 20% chance of error

Leon Congress 2019

School of Veterinary Medicine
University of Pennsylvania



Leon Congress 2019

School of Veterinary Medicine
University of Pennsylvania

Fungal Culture

Detects fungal spores on the hair coat
False positive and false negatives are problematic
"Positive" vs. "Negative" results are not adequate

- Need a semi-quantitative assessment of fungal culture growth
- Colony forming units/plate
- Toothbrush fungal culture

Microscopic confirmation



Leon Congress 2019

School of Veterinary Medicine
University of Pennsylvania

Short Communication

Evaluation of incubation time for *Microsporium canis* dermatophyte cultures

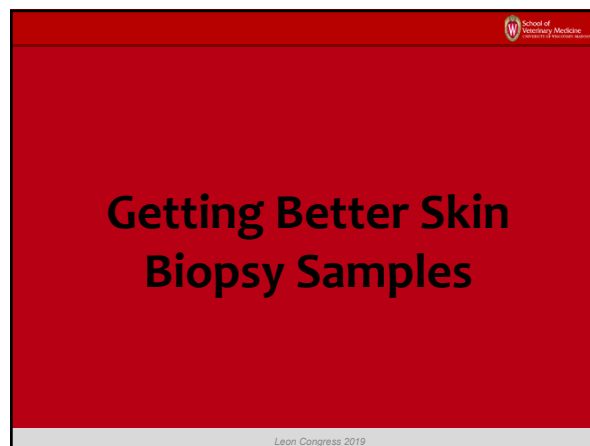

Rebecca Stuntebeck, Karen A Moriello and Maria Verbrugge



Only need 14 days to finalize no growth cultures

Journal of Feline Medicine and Surgery
SAGE
© The Author(s) 2017
Reprints and permissions:
sagepub.com/journalsPermissions.nav
DOI: 10.1177/1098175517700000
The paper was handled and processed
by the American Editorial Office (AEO)
for publication in JFMS

Leon Congress 2019



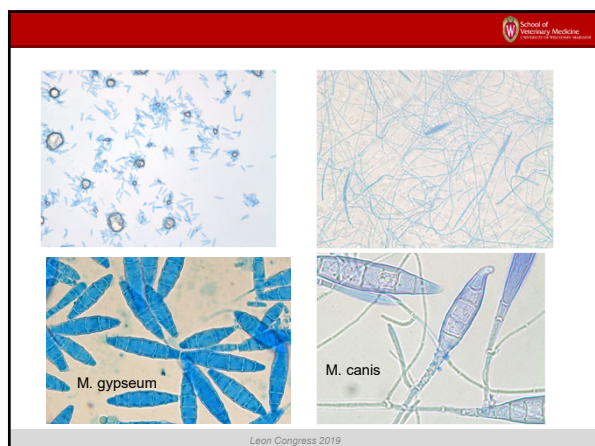
Practice tip: let stained slide set for 10-15 minutes before examination

Allowing the sample to sit for 10 to 15 minutes will allow the stain to be absorbed intracellularly making it easier to see macroconidia

Leon Congress 2019

Skin Biopsy Practice Tips

Leon Congress 2019

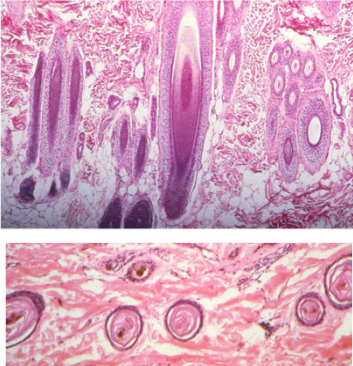


Skin Biopsy Punch Sizes: 2, 4, 6, mm???

Samples shrink up to 50% in formalin, use 8 mm skin biopsy punch

Reagan, 2016 AJVR

Leon Congress 2019



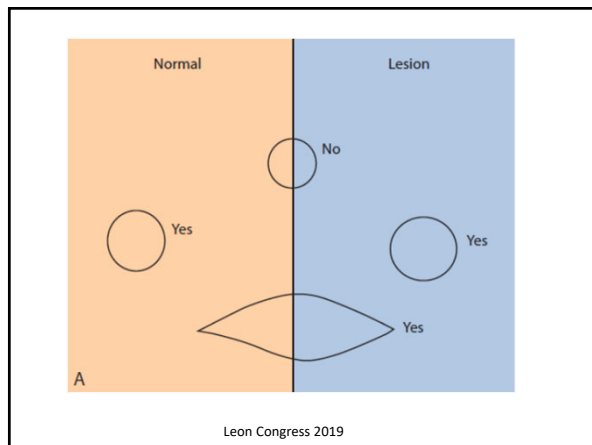
Don't prep the skin

Use 8 mm biopsy punch-TAKE SEVERAL

Do not take junctional specimens

Don't clip hair too short, pathologist uses it to orient specimen

Leon Congress 2019



Thank you for your attention!

Leon Congress 2019